Implant Placement in Site of Plexiform Ameloblastoma After Dredging. A Clinical Report

Regmi S[1], Joshi SP[2], Shrestha P[3], Sah SK[4], Verma A[5], Karna G[6]
[1]PG Resident, Department of Prosthodontics, National Academy of Medical Sciences, Bir Hospital, Kathmandu
[2]Professor, Department of Prosthodontics, National Academy of Medical Sciences, Bir Hospital, Kathmandu
[3]Assistant Professor, Department of Prosthodontics, National Academy of Medical Sciences, Bir Hospital, Kathmandu
[4]Assistant Professor, Department of Prosthodontics, National Academy of Medical Sciences, Bir Hospital, Kathmandu
[5]Assistant Professor, Department of Prosthodontics, National Academy of Medical Sciences, Bir Hospital, Kathmandu
[6]Consultant Oral and Maxillofacial Surgeon, National Academy of Medical Sciences, Bir Hospital, Kathmandu

Abstract

Ameloblastoma is a benign but aggressive neoplasm of odontogenic origin with a predilection of the mandible. It can be of various types based on histopathological features. Follicular and plexiform ameloblastoma are the most common types of ameloblastoma. There are various methods for management of ameloblastoma amongst which dredging is considered a conservative surgical procedure which involves enucleation or deflation and enucleation and repeated removal of scar tissues to accelerate new bone formation. Placement of implant at the site of newly regenerated bone after dredging is completed with repeated examination of tumour mass histopathology. This report documents the placement of implant in newly formed mature bone after successful dredging of plexiform ameloblastoma

Key words: Ameloblastoma, Dredging, Implant

Introduction

Tumours of odontogenic region have wide range of histopathological types and clinical behaviour. Among all the swelling of oral cavity, 9% are odontogenic tumours in which ameloblastoma accounts for 1% of lesions.[1] Ameloblastoma is described by Robinson (1937) as a benign tumour that is usually unicentric, non-functional, intermittent in growth, anatomically benign and clinically persistent.[2] According to histopathological classification, ameoblastoma is divided into follicular, plexiform, acanthomatous, basal cell and granular types.[3] Mostly the tumour is asymptomatic.

Surgical resection with wide margins has been considered the modalities for the treatment of ameloblastoma due to high chances of recurrences.[3, 4] Dredging is a newer conservative means for surgical treatment of ameloblastoma, it involves repeated deflation and enucleation to removes scar tissues from the bone cavity.[3]

It has been reported that dredging method has very low recurrences in comparison to surgical resections.[4] for the treatment of ameloblastoma but continuous and regular follow up is warranted.[5, 6]

Dredging is applied within 2-3 months interval to accelerate new bone formation and eliminate tumour cell nests. Histopathological examination of all specimens are essential to ensure elimination of residual tumour cells and prevent recurrence. The follow up in the dredging

Conflict of Interest: No

***Corresponding Author**
Dr. Sirishchandra Regmi, PG Resident
Department of Prosthodontics, National Academy of Medical Sciences, Bir Hospital ,Kathmandu ,Nepal
E-mail: drsirish27@gmail.com

methods begins when the tumour cells cannot be identified in microscopic examinations of two consecutives dredging specimens.

This article describes the placement of implant in the region of plexiform ameloblastoma managed surgically after repeated dredging. During dredging procedure, the overlying tooth and cystic lining was removed. After successful treatment of tumour mass, the cavity was allowed to heal and after eight months an implant was placed in relation to the missing teeth in newly formed mature bone.

Case Report

Based on histo-pathology, ameloblastoma is classified into: follicular, acanthomatous, granular cell, basal cell, and plexiform (5). Follicu-lar and plexiform ameloblastomas are the most common, with incidence rates of 27.7% and 21.1% respectively, followed by acanthomatous and the granular types(6) 18 years old girl reported to the Department of Oral and Maxillofacial surgery at National Academy of Medical Sciences, Bir Hospital with the complain of swelling over right cheek region for a year. Swelling was progressive, firm in consistency without pain over right buccal region. There was mild tenderness on palpation.

On examination Cone beam CT revealed bone tumor compatible with ameloblastoma on the right mandibular ramus. Soft tissue section revealed tumor mass arranged in interconnecting strands of cells. Each of these strands was bounded by a layer of tall columnar ameloblast like cells and between these two layers there was presence of stellate reticulum like cells with presence of areas of cystic degeneration. Epithelium showed presence of double rows of columnar cells back-to-back. Connective tissue showed bundles of collagen fibers with inflammatory infiltrate and endothelial cells with red blood cells suggestive of plexiform ameloblastoma.

Materials and Methods

After histopathological confirmation (Fig. 2, 4) of absence of tumour cells following successful dredging, Cone beam CT scan was done and treatment planning was done in Galaxis software to rehabilitate the missing tooth. Impression of upper and lower arch were taken with irreversible hydrocolloid and diagnostic casts were made in type III Dental stone (Kalstone)

Surgical template was made in relation to the missing tooth and implant placement was done with implant size 5 * 8mm (Copasky, Bredent) (Fig. 5). After radiographic confirmation simple interrupted sutures (Polydioxanone 4.0) were placed and post-operative instructions were given.The patient was advised to take antibiotics and analgesics and recalled for follow up after one week.After four months, gingival former was placed and proper running room (Fig. 7) was obtained after two week of healing. Open tray impression (Fig. 8) was taken and monolithic zirconia crown was fabricated (Fig. 10) and placed after occlusal adjustment was done after placement of implant crown (Fig.12) Patient was given proper instructions for oral hygiene maintenance and was asked to follow up after 6 months.

Figure 1: 1st Dredging

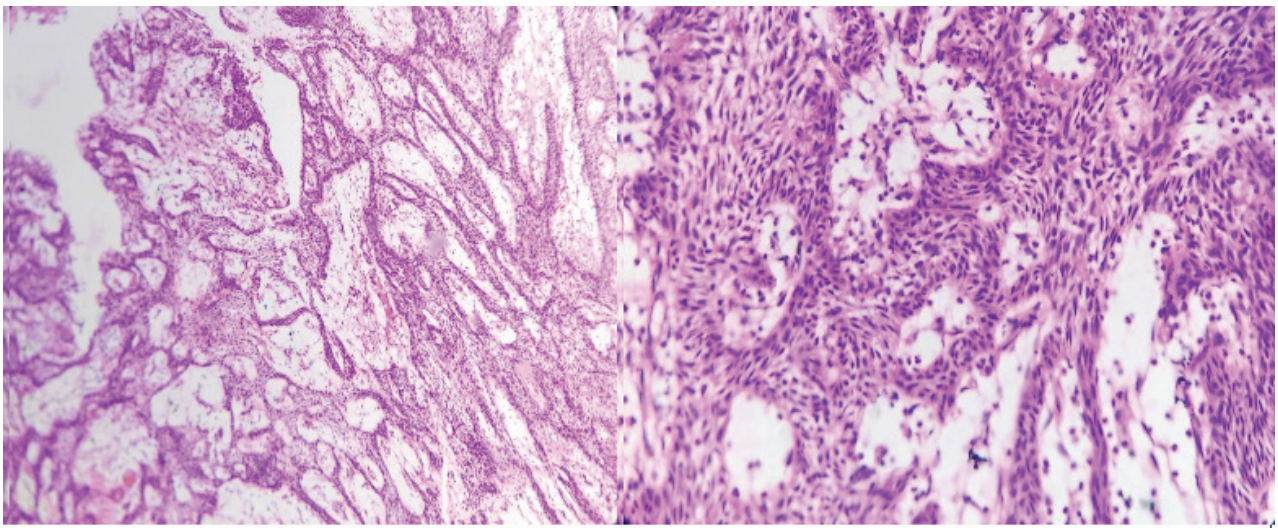

Figure 2: Histopathology after dredging

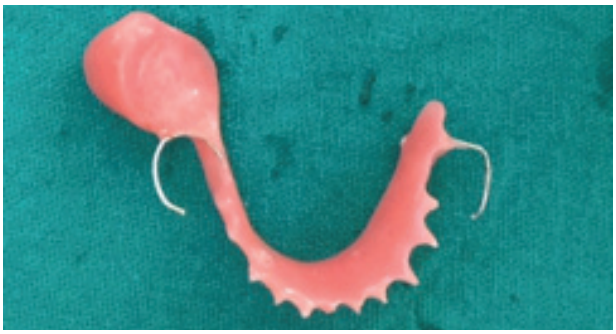

Figure 3: Acrylic splint

Figure 4: Healing after dredging

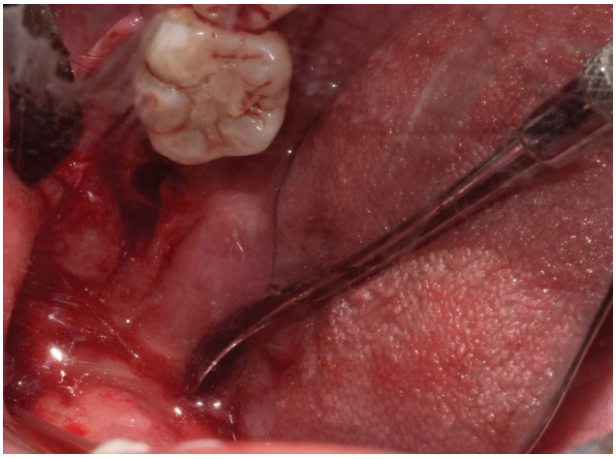

Figure 5: Incision and flap reflection

Figure 6: Radiograph after Fixture Placement

Figure 7: Running room after healing abutment

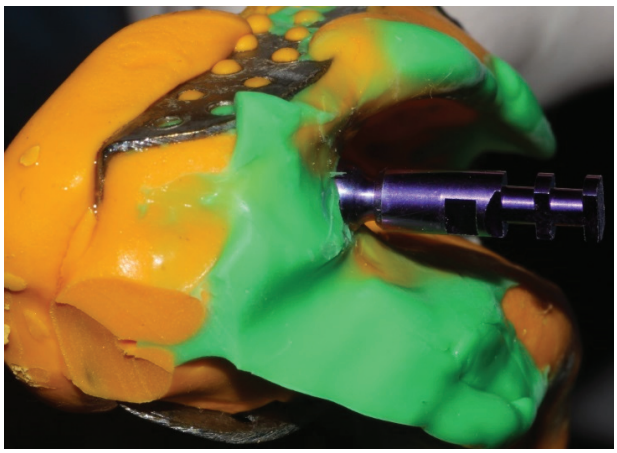

Figure 8: Open tray Impression

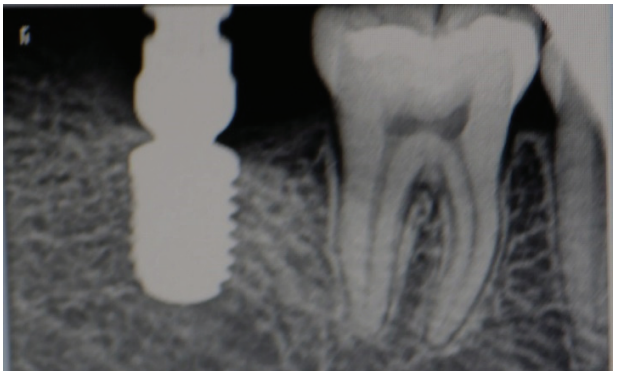

Figure 9: Confirmation for fit of transfer coping in open tray impression

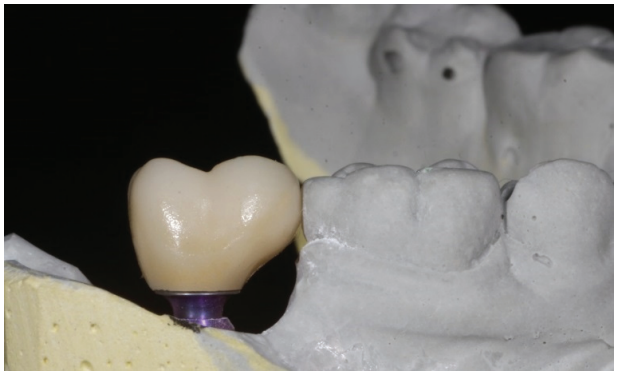

Figure 10: Monolithic zirconia Crown

Figure11: Final crown in position

Figure 12 : Occlusal view after crown placement

Figure 13 : Occlusal evaluation

Figure 14: Radiographic view after crown placement

Discussion

Ameloblastoma is a benign epithelial odontogenic tumour but is often aggressive and destructive, with the capacity to attain great size, erode bone and invade adjacent structures.[7] Ameloblastoma is mainly localized in the third molar–ramus area of the mandible. There are various methods implicated in management of ameloblastoma[8] which includes enucleation, marsupialization, curettage, treatment with Carnoy's solution and surgical resection with immediate reconstructions with free vascularized flaps. Of these, dredging is a newer and conservative modality for the management of ameloblastoma.[9]

After extraction of overlying tooth and removal of healing scar tissue during dredging hematoma, blood clots, coagulation, granulation tissue, or immature fibrous connective tissue formation generally develops during two weeks after surgery.[10, 11] Bone formation develops from the wall and base of the socket to the socket mouth, and a hard internal or external callus develops into more organized bone tissues during the fracture healing.[12] These phases continue for three to five weeks in extraction wound healing and one to three/ four months in fracture healing.[13]

Although the exact mechanism of spontaneous regeneration of the mandible is not clearly understood, several influential factors have been taken into consideration. These include preservation and intactness of the periosteum, the age of patient, presence of local infection, post-operative immobilization, and functional or mechanical stress on the mandibular stumps.[14,15]

New bone formation occurs following tooth extraction and subsequent removal of tumour mass by dredging. The bone is initially woven bone and it matures to lamellar bone later on. Delayed placement of implant was planned in this case with the placement of monolithic Zirconia crown.

Conclusion

Dredging is a newer conservative methodology for treatment of ameloblastoma. The natural bone filled area after successful dredging can be prosthetically rehabilitated with implant supported restorations..

References

1. McClary A, West R, McClary A, Pollack J, Fischbein N, Holsinger C, et al. Ameloblastoma: a clinical review and trends in management. Eur Arch Oto-Rhino-L 2016;273(7):1649-61.

2. Robinson H. Ameloblastoma: a survey of 379 cases from literature. Arch Pathol Lab Med. 1937;23:831-43.
3. Sadat S, Ahmed M. " Dredging Method"-A Conservative Surgical Approach for the Treatment of Ameloblastoma of Jaw. J Bangladesh Coll Phys Surg. 2011;29(2):72-7.
4. Kawamura M. A proposal for the treatment of ameloblastoma. J Oral Maxillofac Surg. 1983;29:765.
5. Müller H, Slootweg P. The ameloblastoma, the controversial approach to therapy. J Oral Maxillofac Surg. 1985;13:79-84.
6. Waldron C. Ameloblastoma in perspective. Oral Surg. 1966;24(4):331-33.
7. Iordanidis S, Makos C, Dimitrakopoulos J, Kariki H. Ameloblastoma of the maxilla. Case report. Aust Dent J. 1999;44(1):51-5.
8. Pindborg J. Histological typing of odontogenic tumours, jaw cysts, and allied lesions. J Clin Pathol. 1971:1-44.
9. Vayvada H, Mola F, Menderes A, Yilmaz M. Surgical management of ameloblastoma in the mandible: segmental mandibulectomy and immediate reconstruction with free fibula or deep circumflex iliac artery flap (evaluation of the long-term esthetic and functional results). J Oral Maxillofac Surg. 2006;64(10):1532-39.
10. Simpson H. The healing of extraction wounds. Br Dent J. 1969;126(12):550-57.
11. Johansen J. Repair of the Post-Extraction Alveolus in the Wistar Rat a Histologic and Autoradiographic Study. Acta Odontol Scand. 1970;28(4):441-61.
12. Wilson J. Watson-Jones fractures and joint injuries: Elsevier India; 2009.
13. Schropp L, Wenzel A, Kostopoulos L, Karring T. Bone healing and soft tissue contour changes following single-tooth extraction: a clinical and radiographic 12-month prospective study. Int J Periodontics Restorative Dent. 2003;23(4).
14. Khodayari A, Khojasteh A, Kiani M, Nayebi A, Mehrdad L, Vahdatinia M. Spontaneous regeneration of the mandible after hemimandibulectomy: report of a case. J Dent. 2011;8(3):152.
15. Adekeye E. Rapid bone regeneration subsequent to subtotal mandibulectomy: Report of an unusual case. Oral Surg Oral Med Oral Pathol. 1977;44(4):521-26.